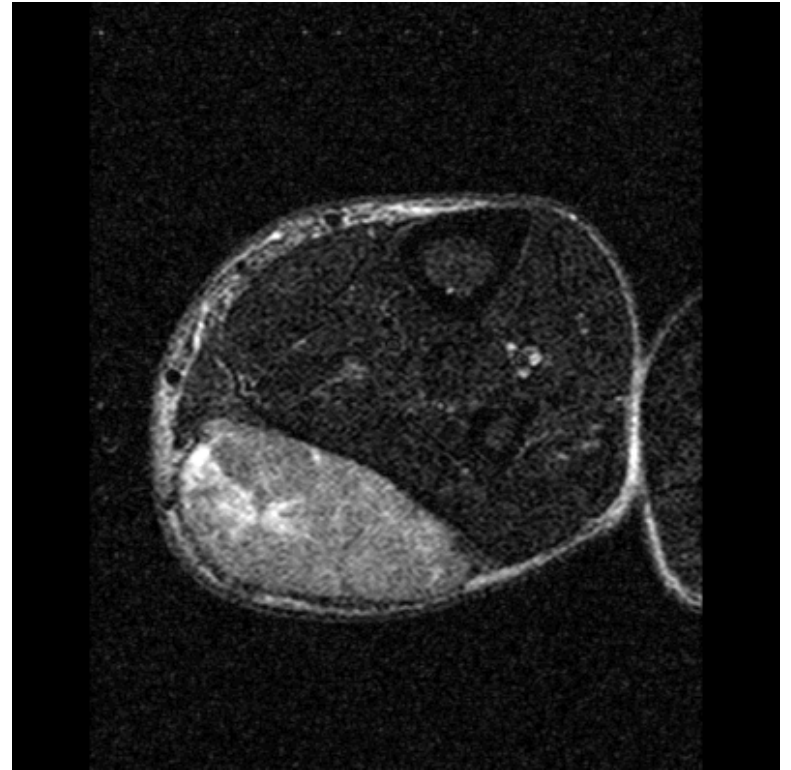
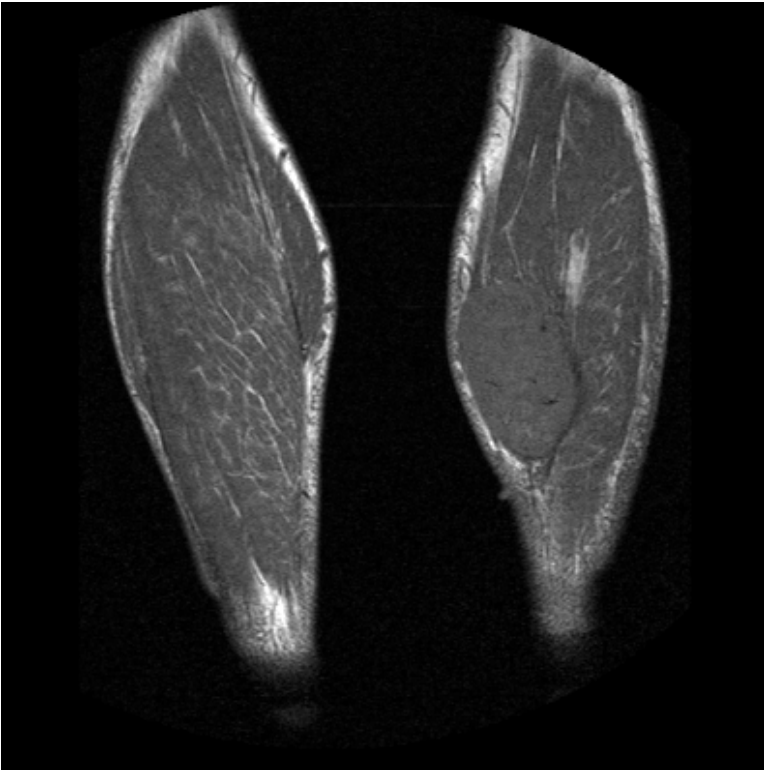



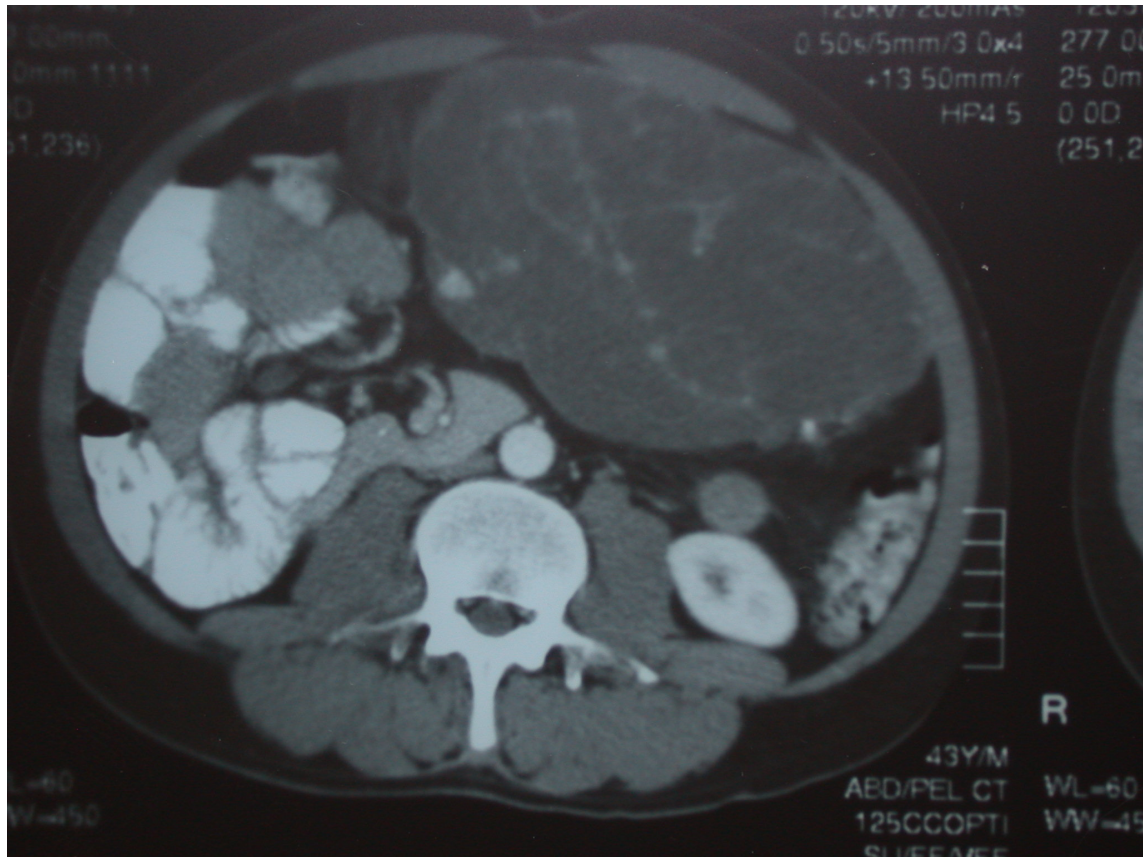
# The Multidisciplinary Approach to Soft Tissue Sarcoma

Jeff Wayne, MD  
Chief, Division of Surgical Oncology  
Professor of Surgery and Dermatology  
Northwestern University Feinberg School of Medicine

# MRI: Leiomyosarcoma of the Calf



# CT: Retroperitoneal Liposarcoma



# NCCN Guidelines: Workup

---



*“Prior to initiation of therapy, all patients should be evaluated and managed by a multidisciplinary team with expertise and experience in sarcoma.”*

NCCN Guidelines, Soft Tissue Sarcoma v2.2016

# Limb-sparing Approach

---

50% amputation rate in 1960's

- Currently 5%

Amputation reserved for tumors not amenable to resection by any other means

- No evidence of distant metastasis

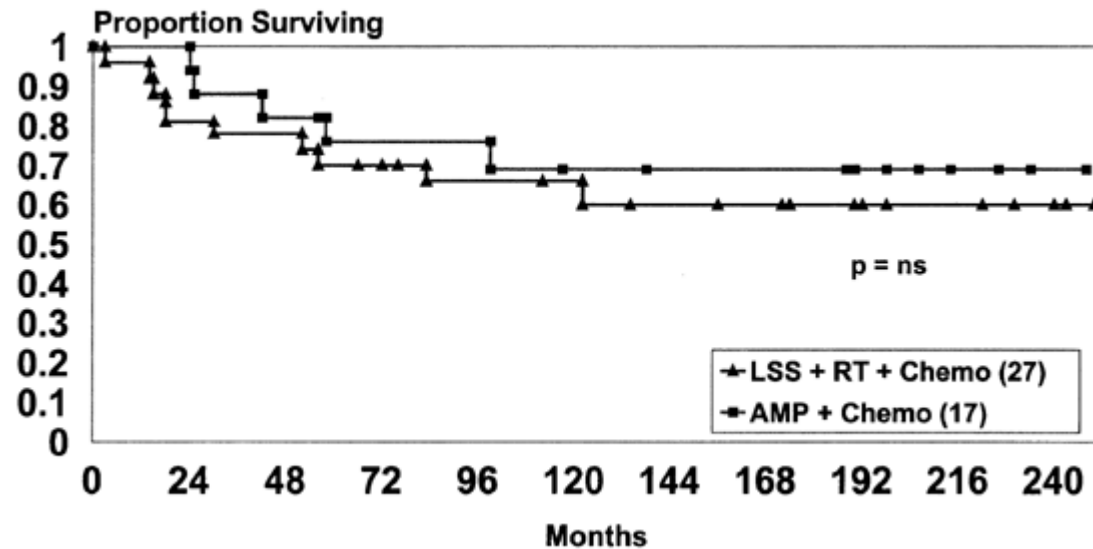
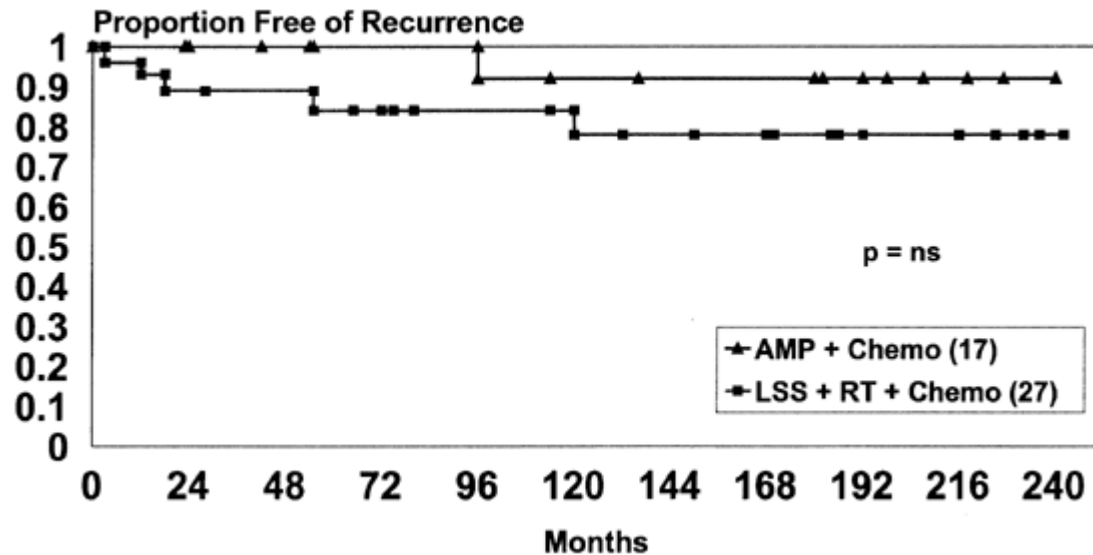
Prospective randomized trial (NCI)

- Local recurrence slightly higher ( $p = 0.06$ )
- No difference in overall survival ( $p = 0.75$ )

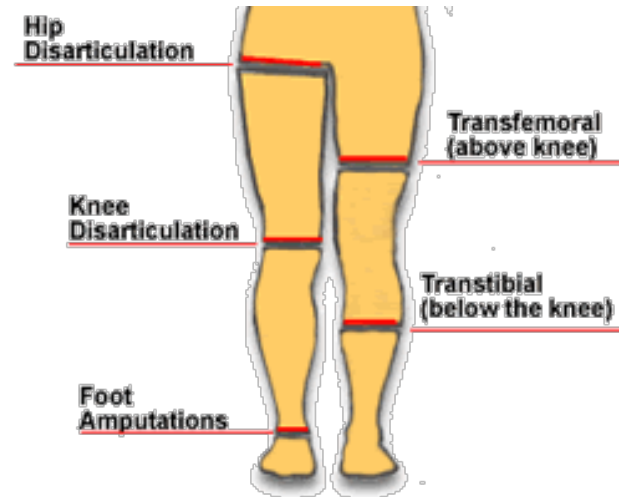
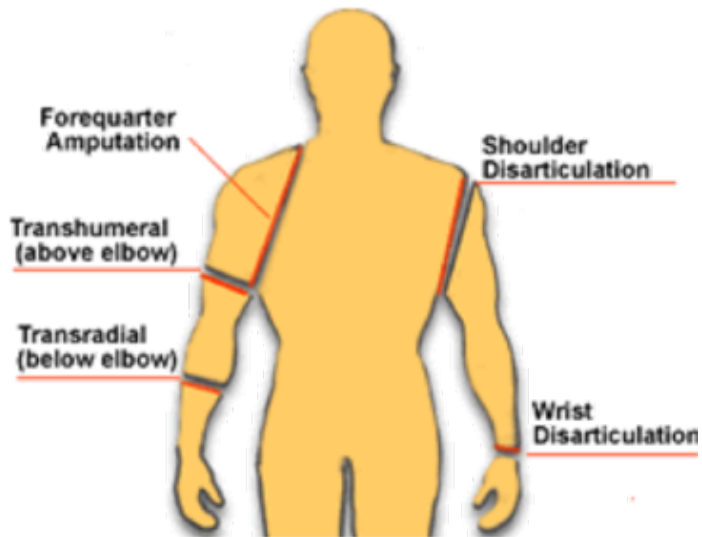
# Dr. Steven Rosenberg



# Rosenberg, Et Al., *Ann Surg*, 1982

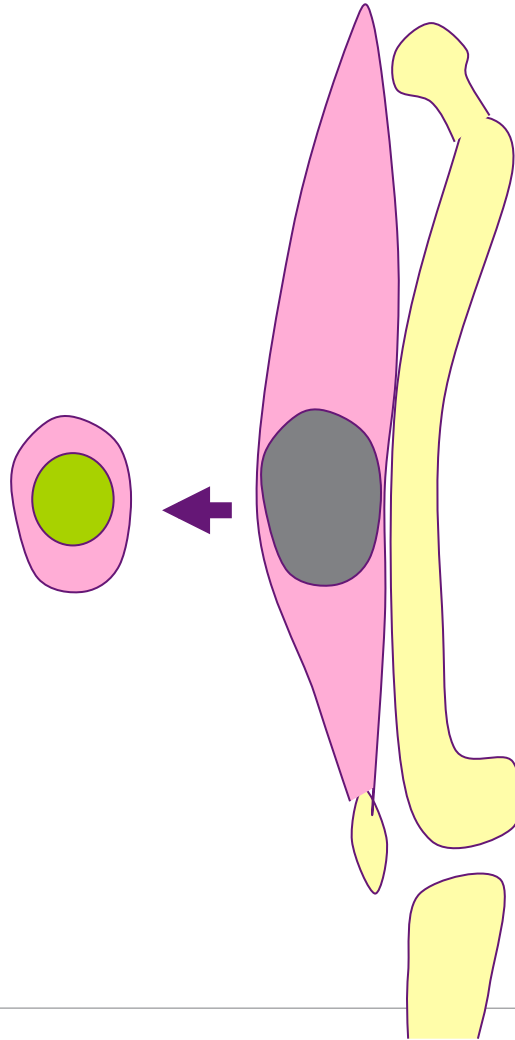


# Amputation

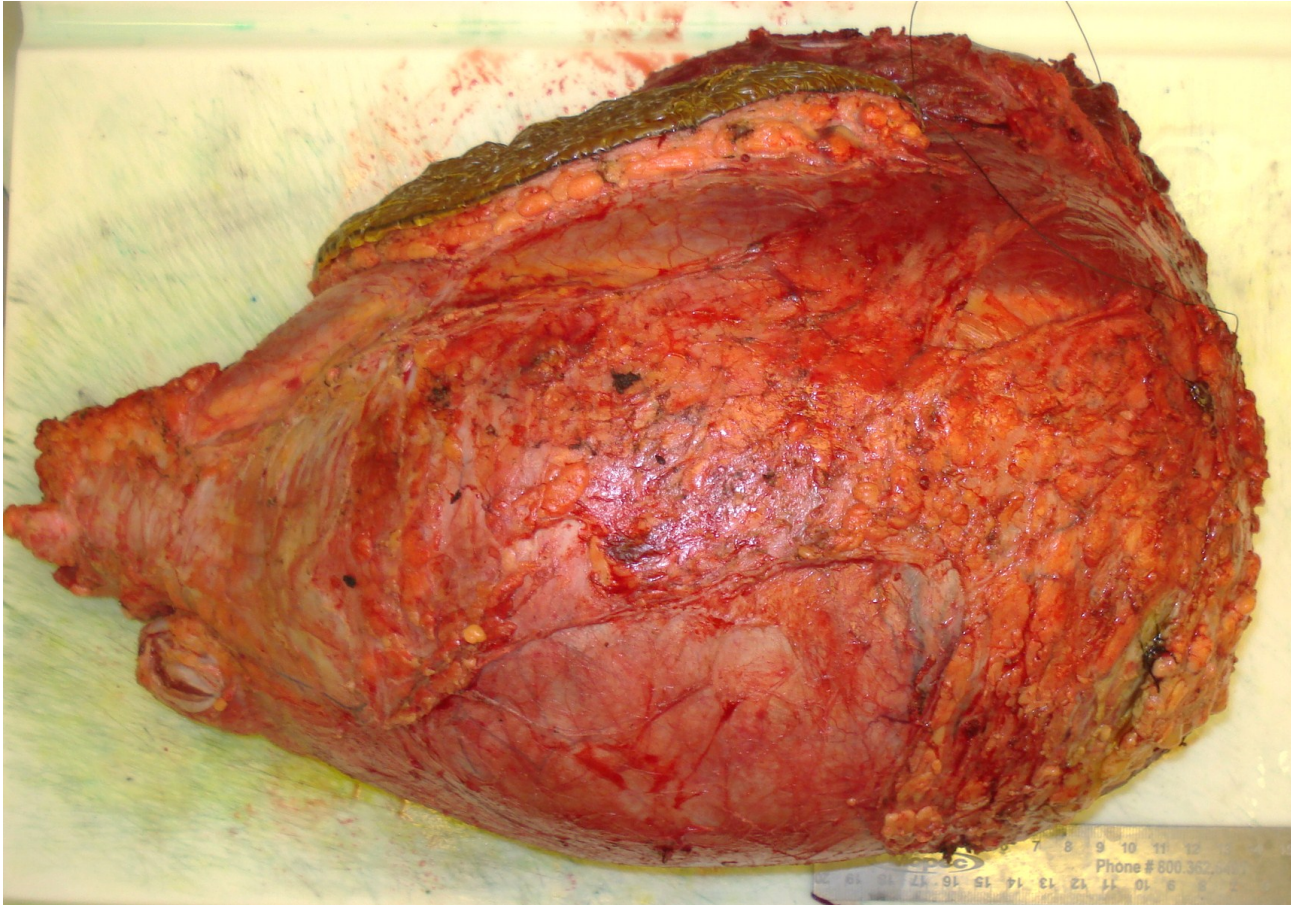




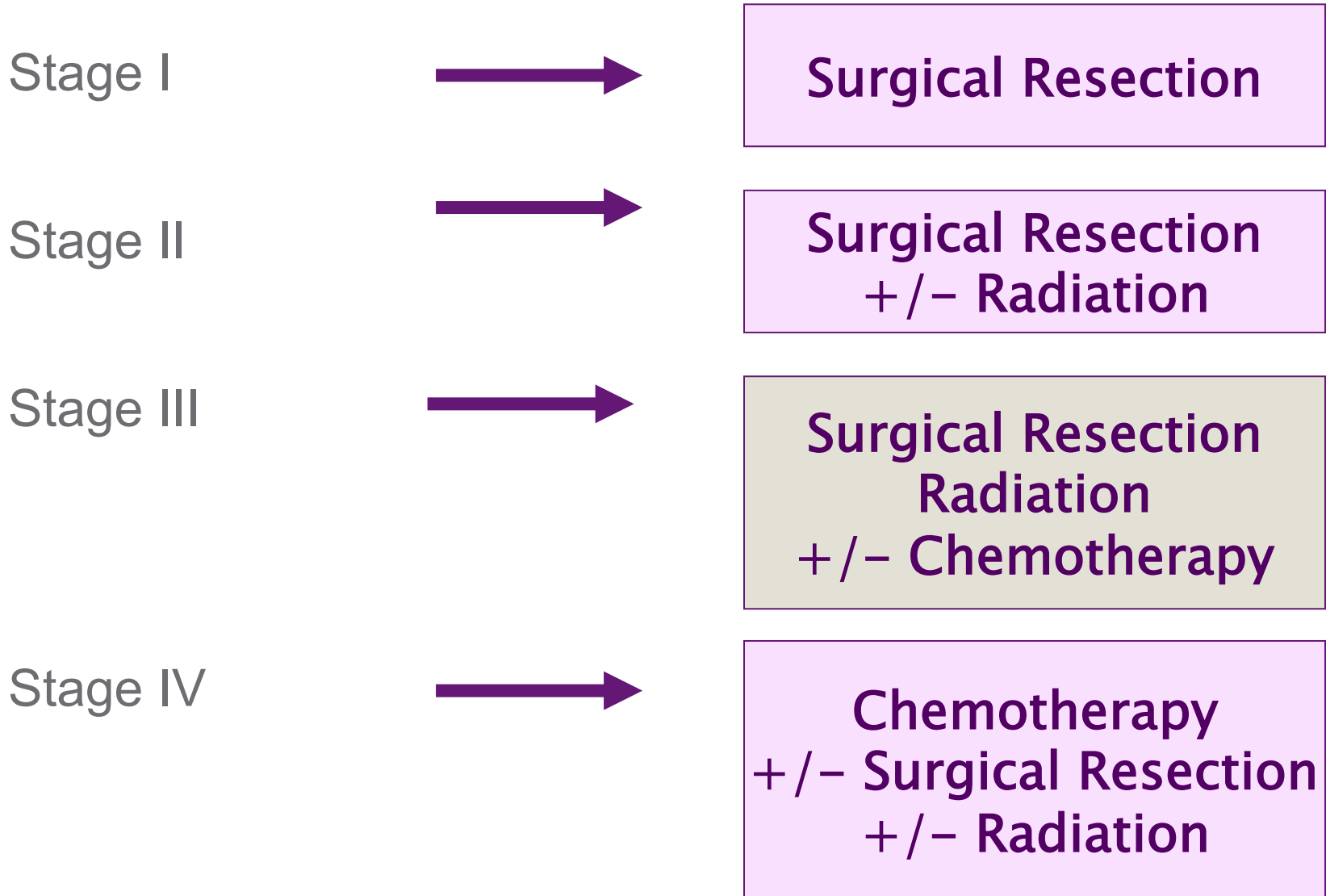
# Wide Surgical Margin



# Wide Surgical Margin



# Management Strategy



# Surgical Reconstruction

Limb-sparing approach is facilitated by availability of plastic and reconstructive surgery techniques

- Complex closure
- STSG
- Rotational flaps
- Free flaps



Thank You!